



**Effects of VigRX on Liver and Kidney of Male Sprague Dawley Rats**

**Investigators:**

Yuthana Smitasiri

Chainarong Tocharus

Sitthisak Pinmongkholgul

Mae Fah Luang University  
Muang District, Chiang Rai 57100  
Thailand

Submitted to:

Dr. Alexander Schauss, PhD, FACN

AIBMR Life Sciences, Inc.

**Nov. 30 , 2005**

## **Abstract**

The aim of this project was to investigate the effects of 2 dosages of VigRX i.e. 15 and 30 mg/kg/D fed to male Sprague Dawley rats everyday for 14 consecutive days on the liver and kidney of these rats .

It was found that only VigRX at the dosage of 30 mg/kg/D could significantly decrease the liver weight. Histopathological section of both liver and kidney showed that both dosages of VigRX did not show any pathological effects on both organs when compared with the control group.

It was concluded that treatment of VigRX continuously for 14 consecutive days had no pathological effect on the liver and kidney of male Sprague Dawley rats.

## **Introduction**

VigRX is a product that contains Asian ginseng root , Saw palmetto berry , Ginkgo biloba leaf , Hawthorn berry , Muira pauma bark extract , Catuaba bark extract , Cuscuta seed extract and Epimedium leaf extract . It is claimed that VigRX can improve erectile function , erect penile size and sex drive .

Smitasiri et al ( 2005 ) reported that VigRX could induce high sex drive , penile size , penile erection and could increase the sperm density in the male Sprague Dawley rats whereas VigRX had no effect on various organs weight i.e. penis , testes , epididymis , seminal vesicle , prostate gland , adrenal gland , pituitary gland and spleen but VigRX had some effects on liver and kidney by decreasing the weight of both organs significantly .

## **Aim of this project**

The aim of this project is to investigate the effects of VigRX on liver and kidney of the male Sprague Dawley rats.

## **Materials and Methods**

### **1. Preparation of VigRX for testing in rats.**

1.1 VigRX bottles from U.S.

1.2 VigRX will be mixed with distilled water and divided into 2 dosages i.e. 15 and 30 mg. VigRX/kg /rat/day ( Calculate from the recommended dose of VigRX for human : 2 and 4 capsules/70 kg/day ).

### **2. The laboratory rats**

The adult male rats of Sprague Dawley strain will be used in this study. The body weight of adult male rats are during 250-280 grams .

**Note :** All of the rats will be supplied by the National Laboratory Animal Center, Mahidol University and transferred to Mae Fah Luang University by air.

### 3. Rearing of the laboratory rats

All of the laboratory rats are reared in the Animal House of Mae Fah Luang University at the ratio of one rat per cage (stainless steel cage, 8x8x12 inches), in a temperature-controlled room approximately  $24\pm 1$  degrees Centigrade in a room with proper ventilation and a daily light cycle of 12 h light and 12 h dark. All of the rats are fed with rodent feed #082 (Pokkapan Animal Feed Co. Ltd.). During the whole period of the study, sufficient water is provided to these rats *ad libitum*.

### 4. Rat groupings

#### Adult male rats

All rats are allowed to recover in the Animal House for 6 days, then each rat is weighed and the data recorded.

The rats are divided into 3 groups

**Group 1** receives 1 ml of distilled water administered orally/day for 14 consecutive days (10 rats/group)

**Group 2-3** Repeat the same as the control group but receive VigRX at the dosage of 15 and 30 mg/ kg/rat/day respectively for 14 consecutive days (11 rats/group).

Each rat will be weighed every 3 days until the test is completed on Day 14.

On Day 15 , each rat is anaesthetized with nembutal injection intraperitoneally . Blood is collected via cardiac puncture and blood chemistry parameters i.e. BUN , creatinine , serum glutamic oxaloacetic transferase ( SGOT ) , serum glutamic pyruvate transferase ( SGPT ) and alkaline phosphatase will be measured . Then the liver and kidney are removed and weighed using 4 – digital electronic balance ( Mettler : Toledo AB 204 - S ) after that the liver and kidney are sliced and fixed in 10% buffered neutral formalin solution . Both fixed organs will be sectioned and processed for

histopathological section. All of the slides will be examined and reported by histopathologist.

All of the collected datas will be statistically analyzed using ANOVA and LSD .

## **Results**

Studies on the effects of VigRX on body weight, liver and kidney weights of the male rats treated with 2 dosages of VigRX i.e. 15 and 30 mg / kg / D continuously for 14 days compared with the control group revealed that VigRX had no effect on body weight gained ( Fig.1 ) , body weight and kidney weight but still decrease the liver weight significantly ( Table 1 ).

Histopathological section of the liver revealed that there was no difference between the the control and both groups of VigRX ( Table 2 ,Fig .2 ) by considering from fatty degeneration , hepatocyte megalocytosis , lymphoid aggregated periportal area , bile duct proliferation , peliosis hepatitis as the criteria .

Histopathological section of the kidney revealed that there was no difference between the the control and both groups of VigRX ( Table 2 , Fig .3 ) by considering from multifocal tubular cyst , tubular cast , tubulonephrosis as the criteria .

Studies on the effects of VigRX on blood chemistry of male rats ( Table 3 ) revealed that VigRX had no effect on BUN , creatinine , SGOT and alkaline phosphatase but could significantly increase SGPT especially in the VigRX ( 30 mg/kg/D ) - treated group.

**Table 1** Body weight and organs weight of male rats treated with VigRX at different dosages continuously for 14 days compared with the control group on Day 15.

Group	Number of rats	Body weight (g.)	Organ weight (mg%)	
			liver	kidney
Control	10	361.90 ± 19.15	4077.79 ± 209.69	714.72 ± 26.78
VigRX 15 mg /kg/D	11	356.70 ± 25.66	3944.71 ± 210.23	683.43 ± 42.30
VigRX 30 mg /kg/D	11	344.67 ± 25.50	3838.41 ± 196.12*	707.74 ± 41.31

Mean ± S.D. ; \* P < 0.05

**Table 2** Effects of VigRX on liver and kidney histology of male rats compared with the control group.

Organs	Lesions	Control (n = 10)	VigRX (mg / kg / D) (NA/TN)	
			15 (n = 11)	30 (n = 11)
Liver	Fatty degeneration	0/10	0/11	0/11
	Hepatocyte megalocytosis	0/10	0/11	0/11
	Lymphoid aggregated periportal area	0/10	0/11	0/11
	Bile duct proliferation	0/10	0/11	0/11
Kidney	Peliosis hepatitis	0/10	0/11	0/11
	Multifocal tubular cyst	0/10	0/11	0/11
	Tubular cast	0/10	0/11	0/11
	Tubulonephrosis	0/10	0/11	0/11

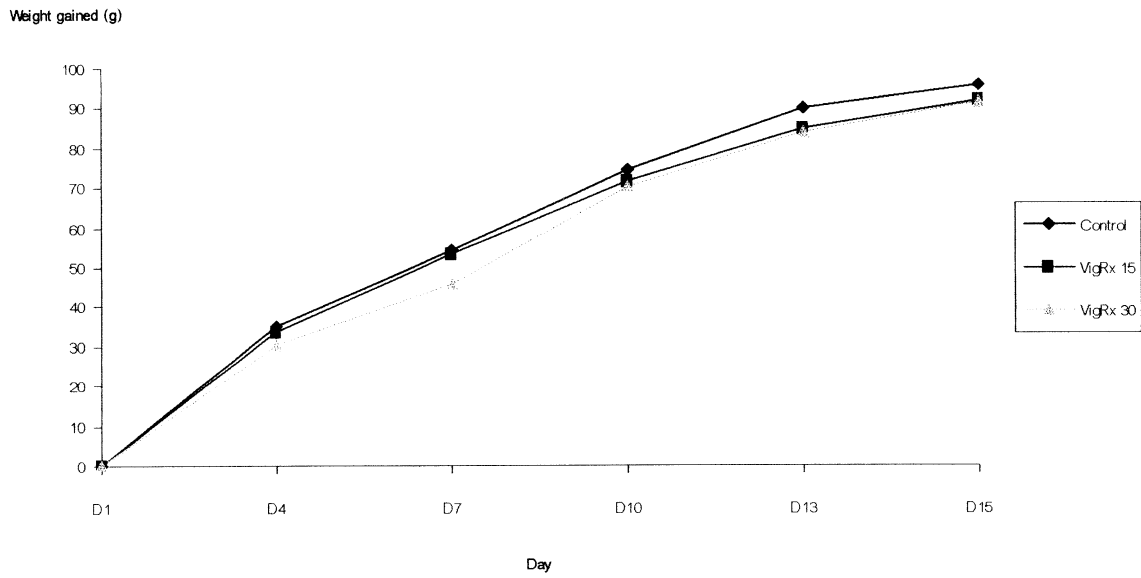
NA/TN = the number of animals with pathological abnormalities / the total number of animals examined, \* P < 0.05

**Table 3** Blood chemistry value of male rats treated with VigRX at different dosages for 14 days compared with the control group on Day 15.

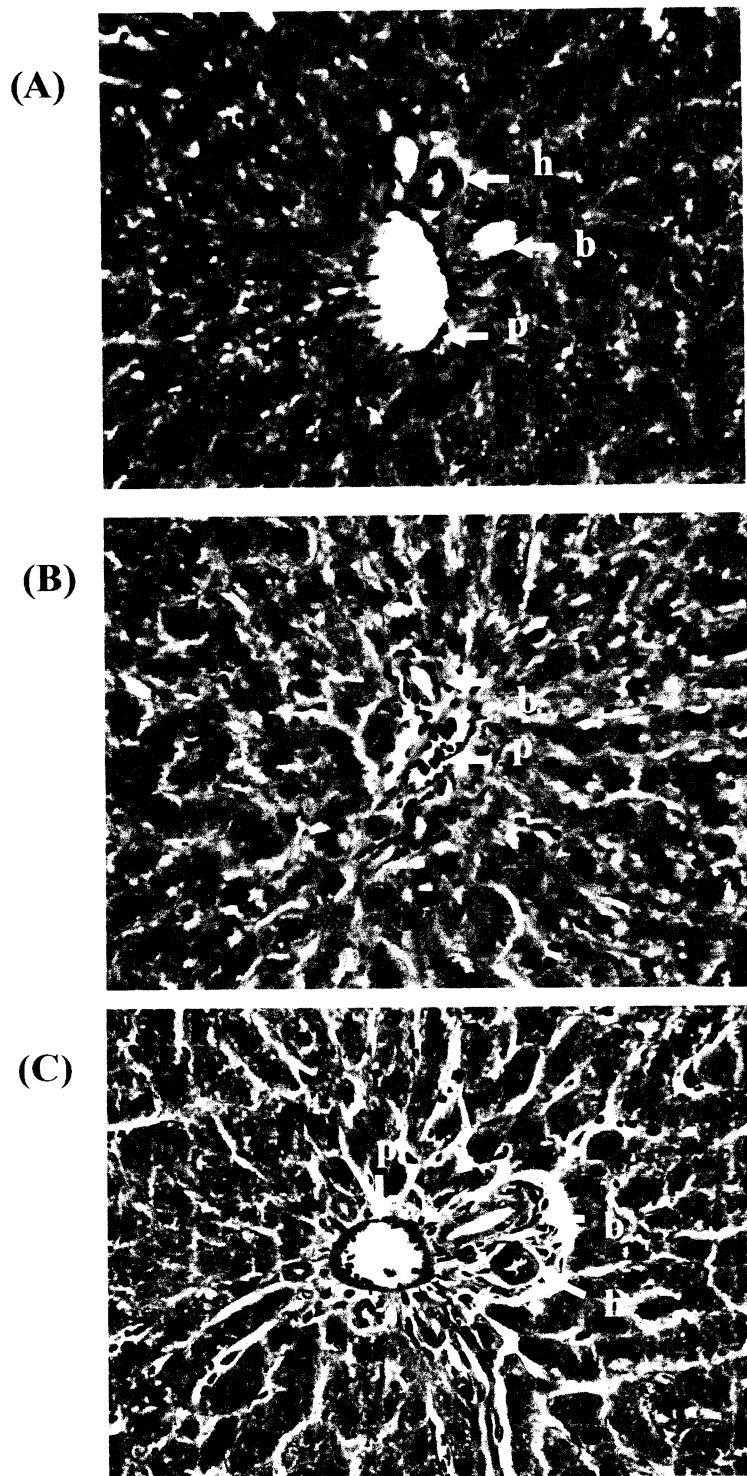
Group	Number of rats	Blood chemistry value				
		BUN	creatinine	SGOT	SGPT	Alk . phosphatase
Control	10	25.50 ± 2.01	0.35 ± 0.10	53.78 ± 21.99	50.00 ± 8.86	172.30 ± 12.55
VigRX 15 mg /kg/D	11	25.70 ± 2.50	0.33 ± 0.05	48.40 ± 8.54	49.80 ± 9.70	163.70 ± 16.28
VigRX 30 mg /kg/D	11	24.33 ± 2.23	0.31 ± 0.07	58.78 ± 19.66	74.67 ± 20.13**	165.25 ± 31.04

Mean ± S.D. ; \*\* P < 0.01

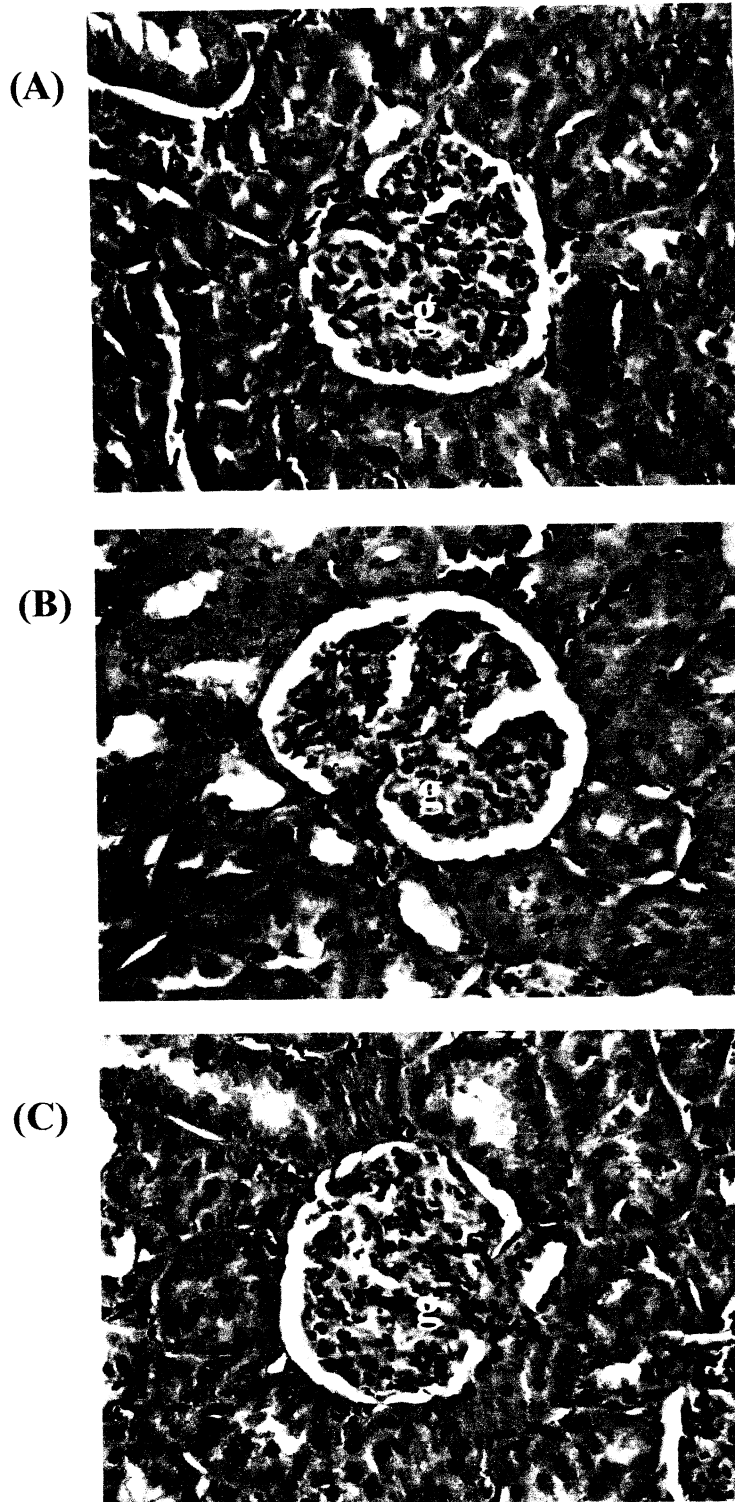




**Fig. 1** Effects of 2 dosages of VigRX on body weight gained of the male rats compared with the control group.



**Fig. 2** Micrographs of liver section from (A) control rat and (B), (C) a rats receiving VigRX at the dosage of 15 and 30 mg/kg /D for 14 days (H&E staining 40X). p; portal vein, h; hepatic artery, b; bile duct



**Figure 3** Micrographs of kidney section from (A) control rat and (B), (C) rat receiving VigRX at the dosage of 15 and 30 mg/kg /D for 14 days (H&E staining 40X). g ; glomerulus

## Discussion

Two – week treatment of both dosages of VigRX i.e. 15 and 30 mg/kg/D did not have any effect on body weight gained and body weight of the male rats . It was suggested that VigRX might have no effect on the body weight.

Studies on the effects of VigRX on liver and kidney weight in this experiment differed from the first time because in this experiment , VigRX at the dosage of 30 mg/kg/D could only significantly decrease the liver weight whereas at first time this dosage of VigRX could significantly decrease both liver and kidney weight ( Smitasiri et al , 2005 ). Even though there was no effect on kidney weight in this experiment but both liver and kidney were histologically sectioned . The results from liver and kidney sections showed that VigRX had no pathological effects on the histology of both liver and kidney . These results suggested that VigRX had no effects on the liver and kidney histology but the mechanism by which VigRX could significantly decrease the liver weight was still unknown .

From these results , it will make sure that treatment of VigRX at the dosages based on human use for 2 weeks in male rats will have no pathological effects on liver and kidney. However, the long term treatment of VigRX on liver, kidney and other organs need further investigations.

## **Conclusion**

Treatment of VigRX at the dosage of 15 and 30 mg/kg/D for 14 days had no effects on body weight gained and body weight of male Sprague Dawley rats. Only VigRX at the dosage of 30 mg/kg/D could significantly decrease the liver weight but had no effect on the kidney weight. Histopathological sections of both organs showed that VigRX had no pathological effects on the histology of both liver and kidney . It was concluded that treatment of VigRX continuously for 2 weeks had no pathological effects on the liver and kidney of the male Sprague Dawley rats even though VigRX could significantly decrease the liver weight .

## **References**

Smitasiri , Y., Tocharus , C., and Pinmongkholgul, S. 2005. Effects of VigRX on sexual behavior, erect penile size, intracavernous pressure, testosterone level, sperm density, and some organs in male Sprague Dawley rats and its long-term effects : First report, Mae Fah Luang University, Chiang Rai.